A 7-year-old domestic longhair cat

# Fine needle aspirate from a subcutaneous mass on the shoulder

Grossly, the mass appeared blackish

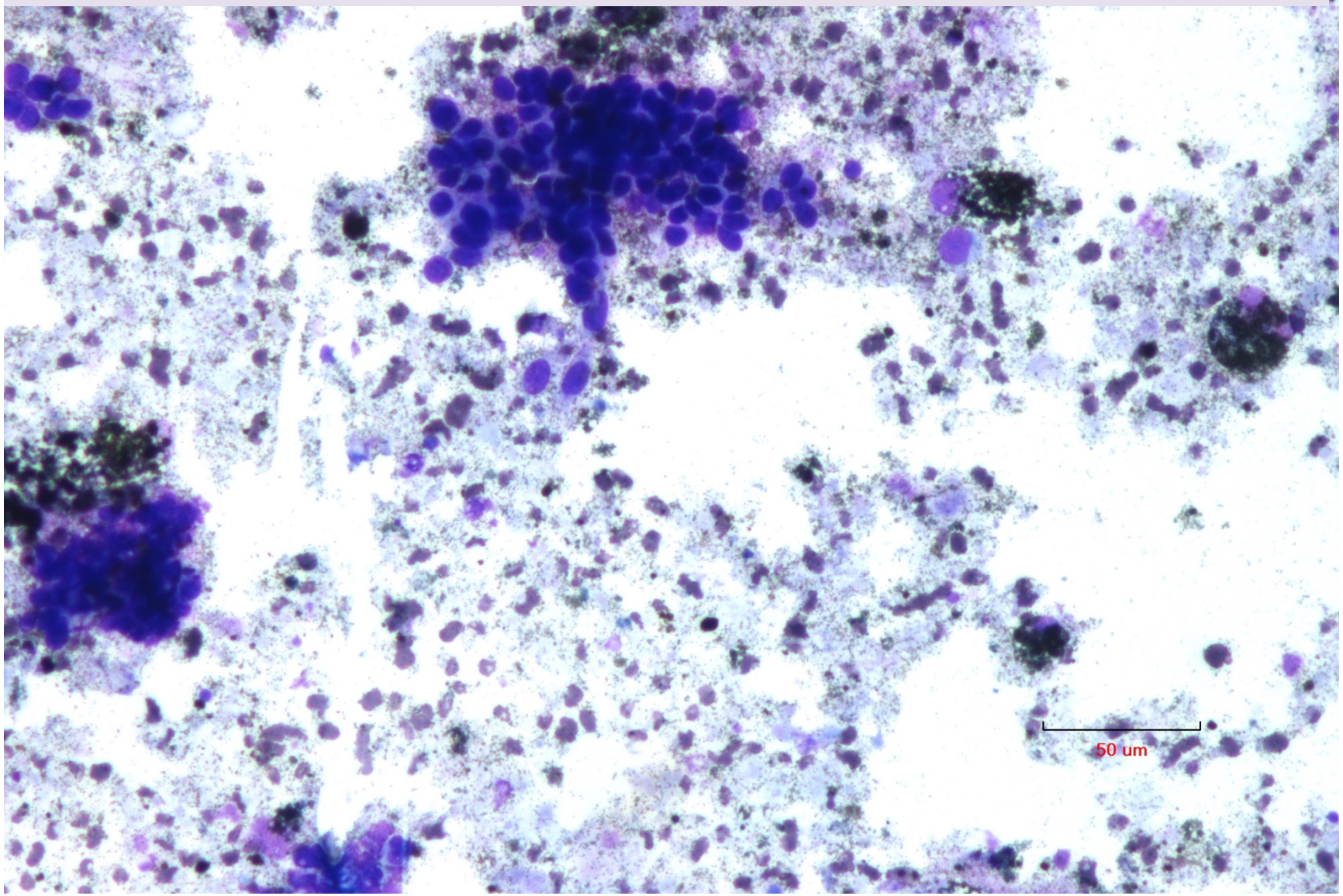

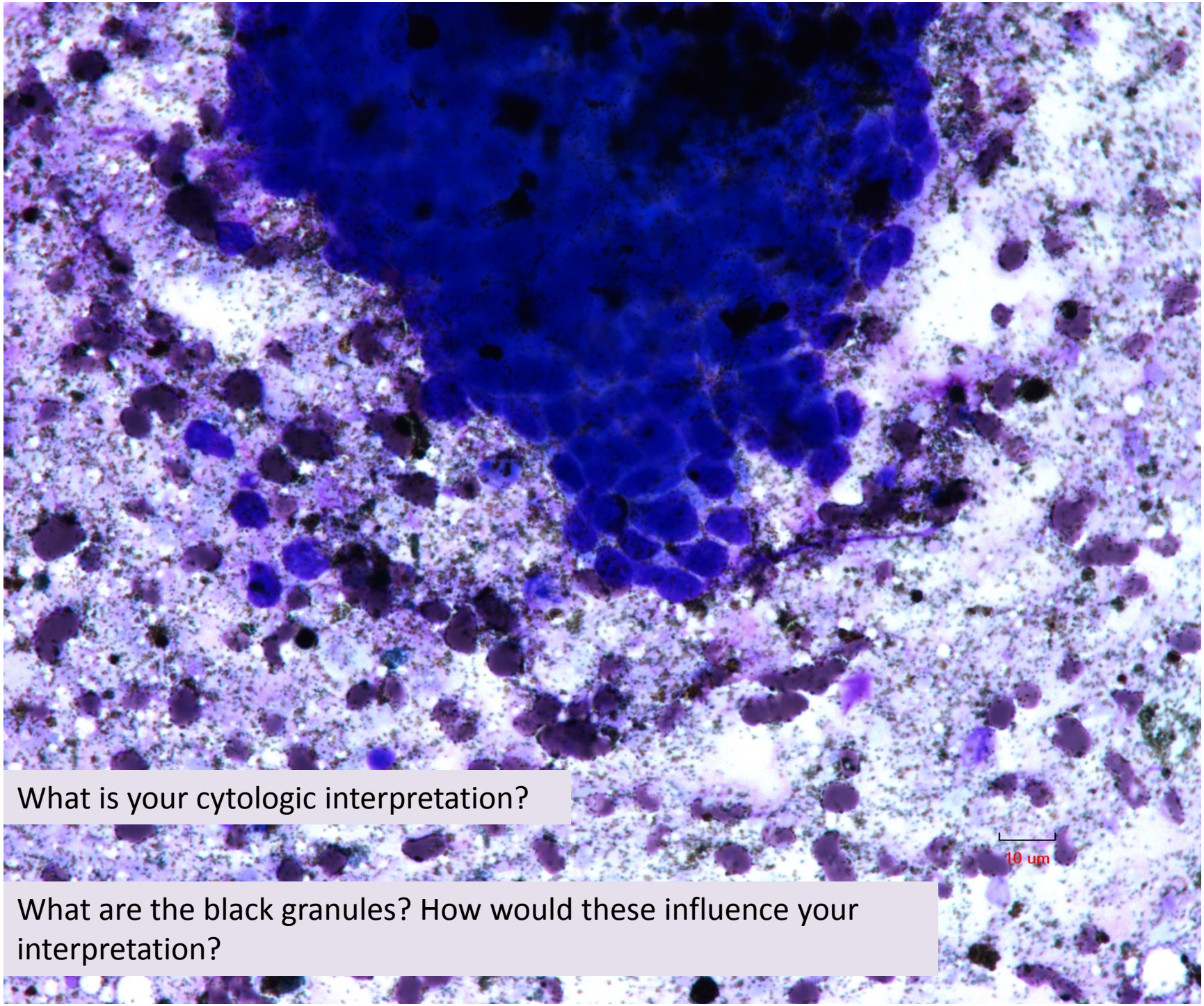


What is your cytologic interpretation?

What are the black granules? How would these influence your interpretation?

# PERTINENT CYTOLOGIC FINDINGS

Uniform epithelial cells with:

- Round to oval nuclei, centrally located
- Small amount of cytoplasm
- High N:C ratio

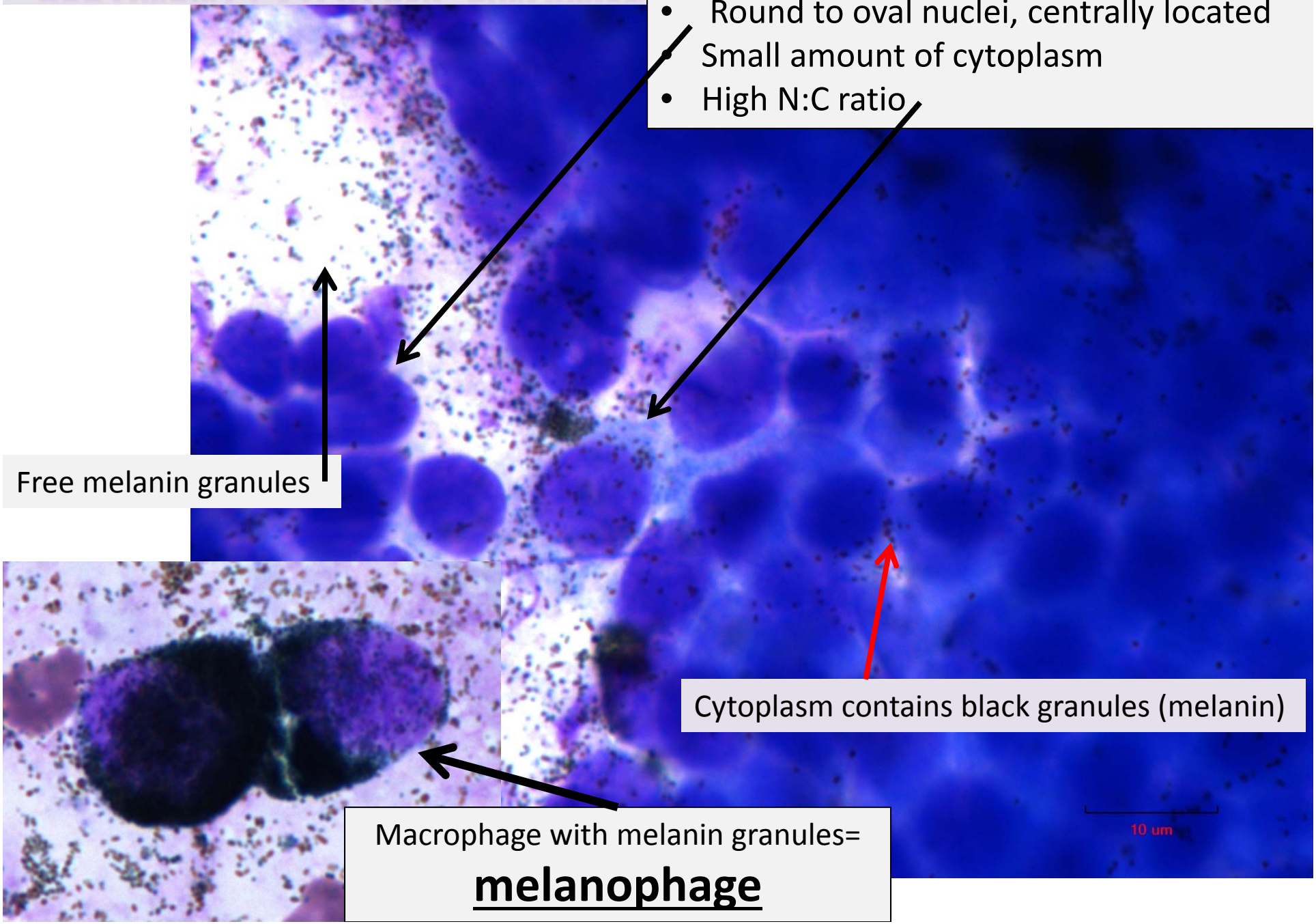


Free melanin granules

Cytoplasm contains black granules (melanin)

Macrophage with melanin granules=

**melanophage**

# Pigmented epithelial tumor
# "basal cell tumor" group

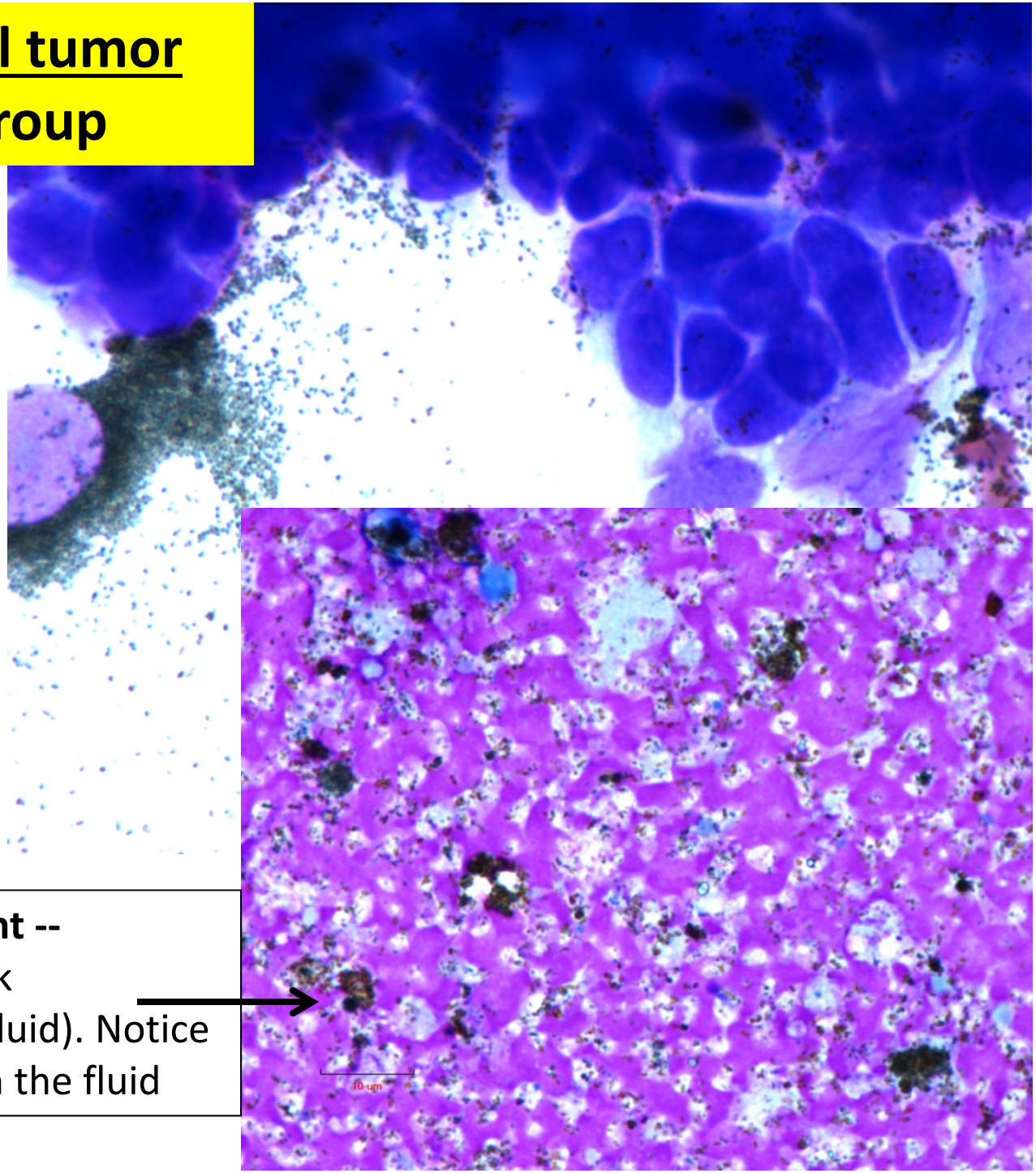


**With a cystic fluid component --** indicated by thick purple-pink background (proteinaceous fluid). Notice the abundant free melanin in the fluid

# “Basal cell tumors”

- Historically, “basal cell tumor” referred to a heterogeneous group of epidermal, trichofollicular and adnexal skin tumors with a common feature of basal cells[1]
  - Recently, this large category has been parsed into more specific entities based on tissue architecture and immunohistochemical features[2,3]
    - **Trichoblastoma** (dogs and cats-most common)
    - **Solid-cystic apocrine ductular adenoma** (cats-common)
    - **Basal cell carcinoma or basal cell epithelioma** (dogs and cats-rare)
    - **Basal cell tumor** (cats-rare)
  - Some of these classifications remain controversial[2,3]
- Because of the reliance for specific classifications on either tissue architecture or immunohistochemical findings, cytologically these tumors are collectively referred to still as either **basal cell tumors** or **cutaneous basilar epithelial neoplasms**[1]

# Discussion

- On histopathologic exam, in addition to the basal cells and cystic structures, there were features of abrupt keratinization, consistent with a **cystic trichoblastoma.**
- Melanin pigmentation can be a prominent feature of all cutaneous basilar epithelial neoplasms, making a cytologic misdiagnosis of melanoma possible.
- Melan A can be useful in differentiating feline cutaneous melanoma from pigmented basal cell tumor[4].

# References


1. Bohn, AA et al. Basal cell tumor or cutaneous basilar epithelial neoplasm? Rethinking the cytologic diagnosis of basal cell tumors. *Vet Clin Pathol.* 2006; 35(4): 449-453.

2. Gross TL, Ihrke PJ, Walder EJ, Affolter VK. Skin disease of the dog and cat, clinical and histopathologic diagnosis ,2nd Ed;625-629.

3. Meuten, DJ. Tumors in Domestic Animals, 4th Ed.; Ch 2: Tumors of the Skin and Soft Tissues. 2002 Iowa State Press (Ames, Iowa).

4. Ramos-Vara JA, Miller MA, Johnson GC, Turnquist SE, Kreeger JM, Watson GL. Melan A and S100 Protein Immunohistochemistry in Feline Melanomas: 48 Cases. Vet Pathol. 2002;39:127-132.