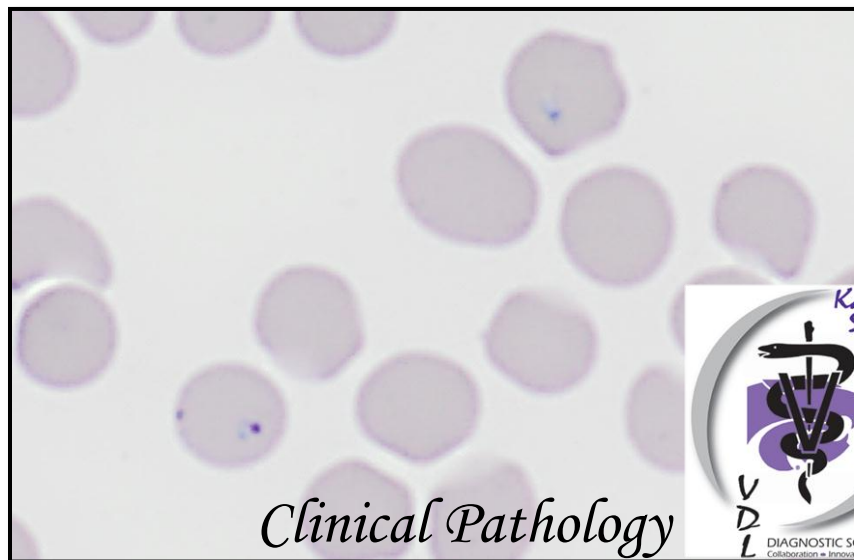
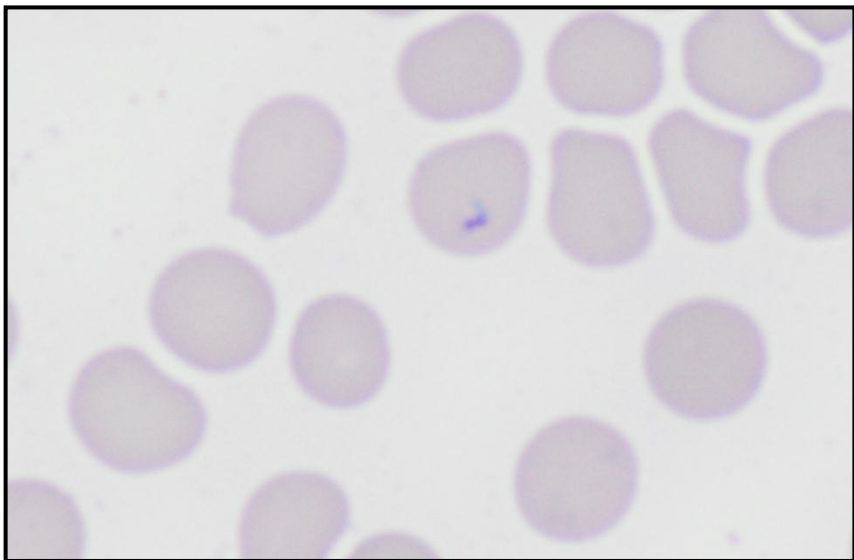
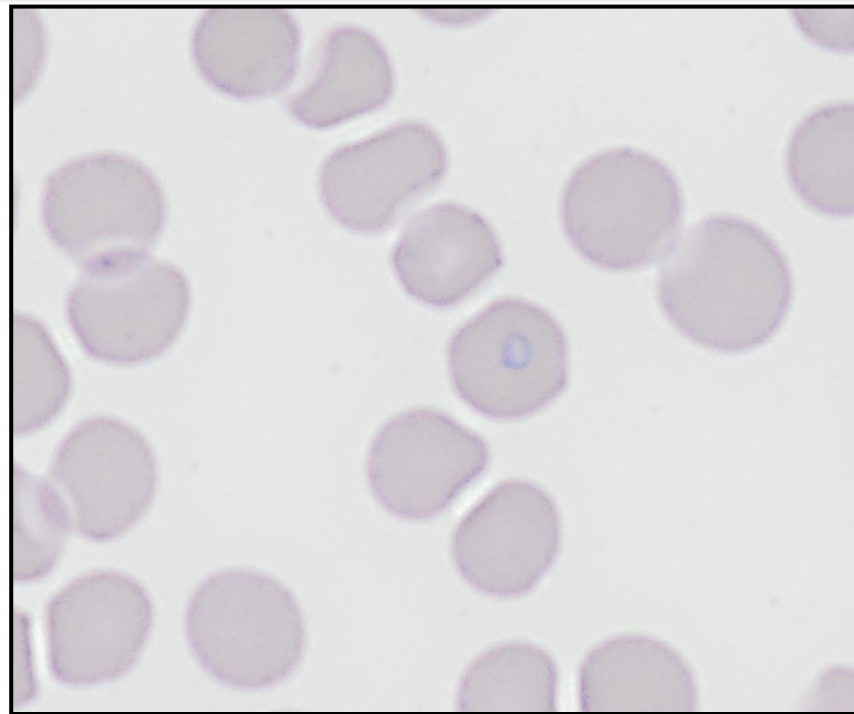
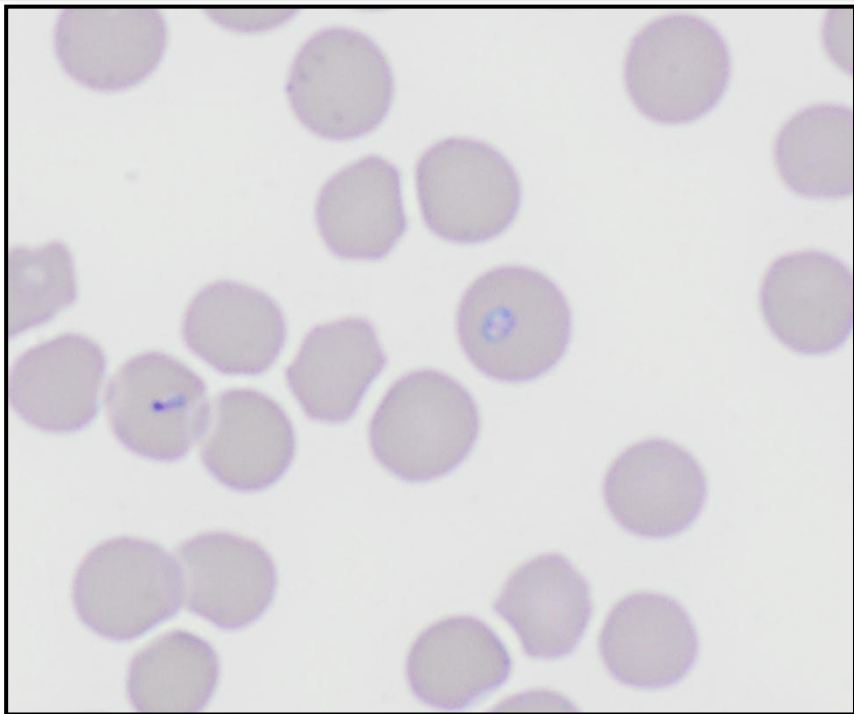


Blood smear from a 7-year-old outdoor cat

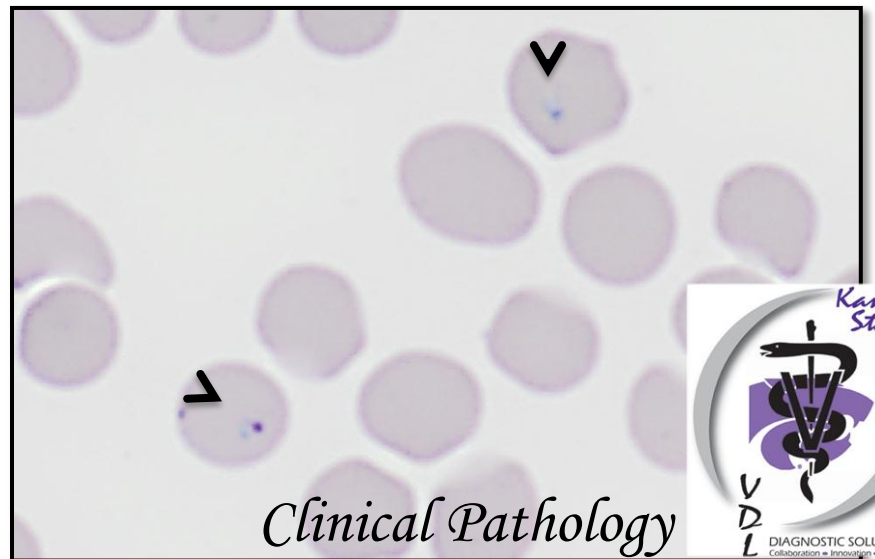
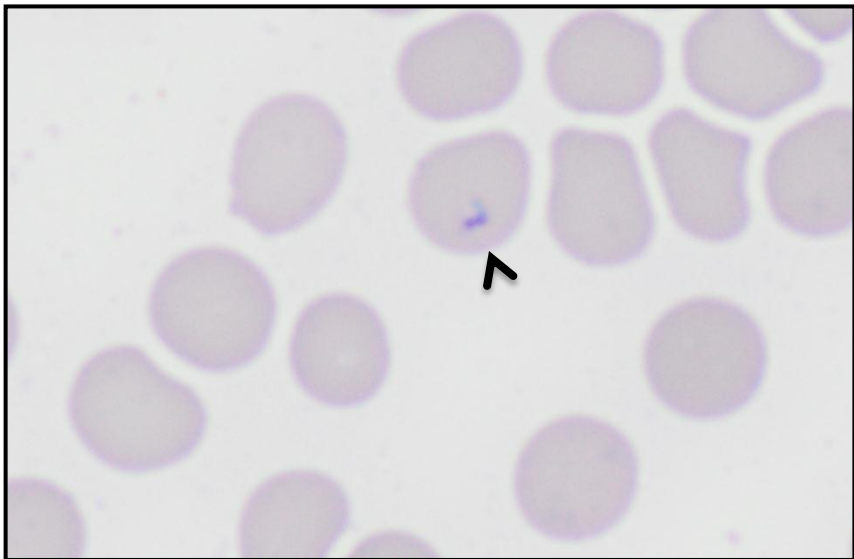
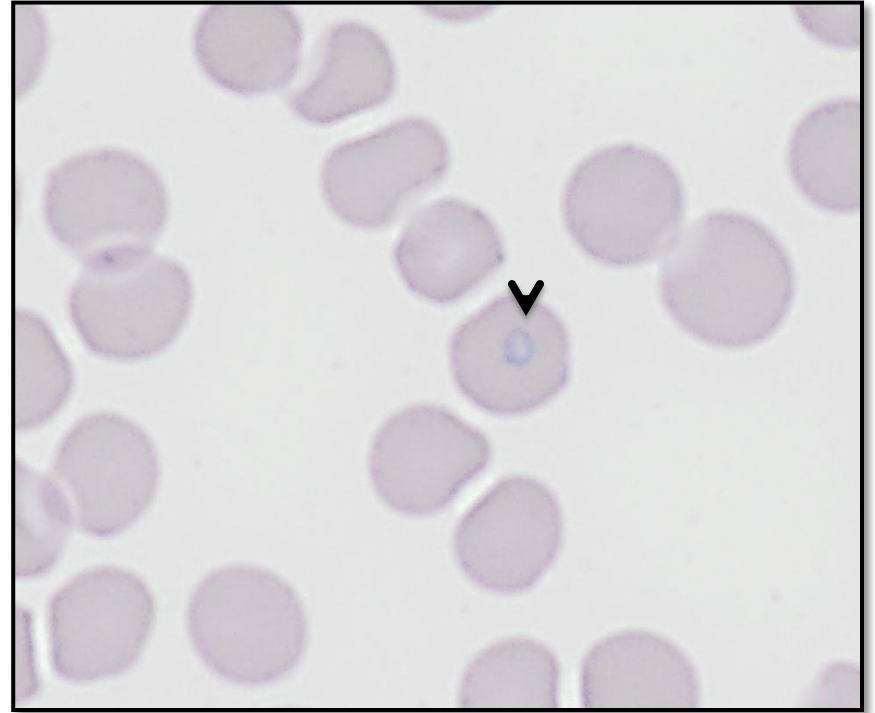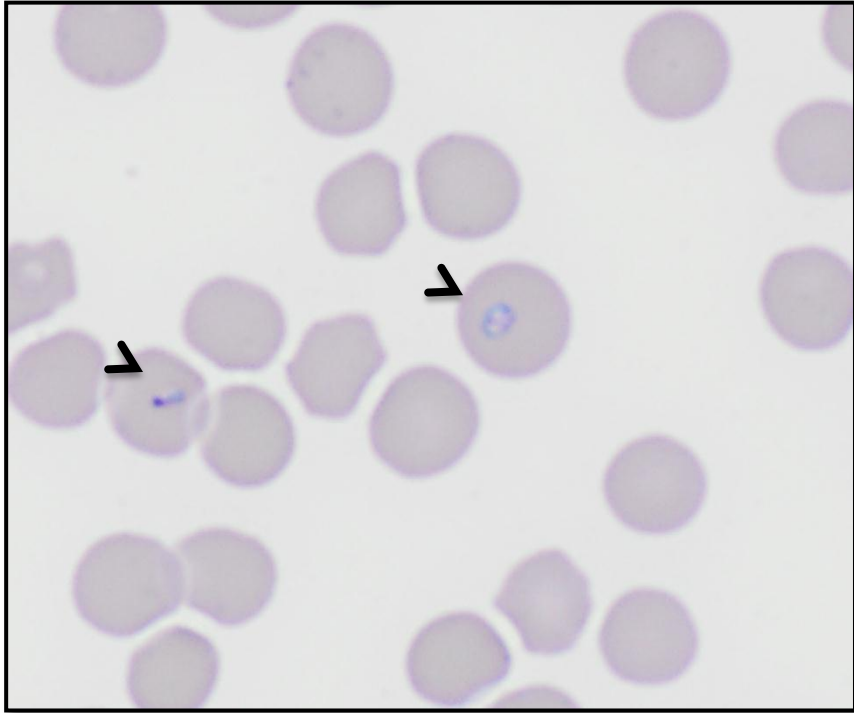
Blood smear from an outdoor cat



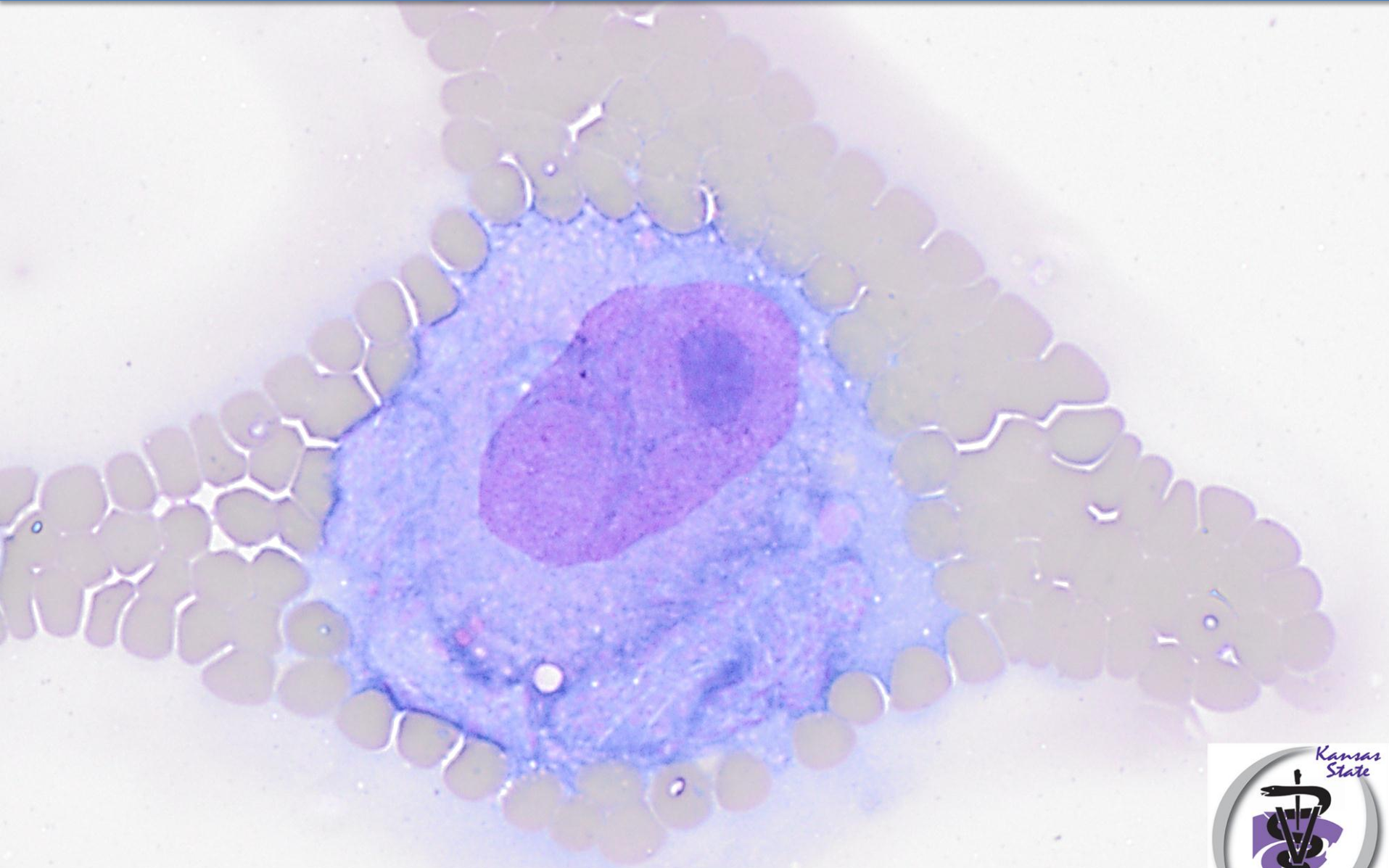
Clinical Pathology



'Signet-ring' shaped Piroplasms within RBCs



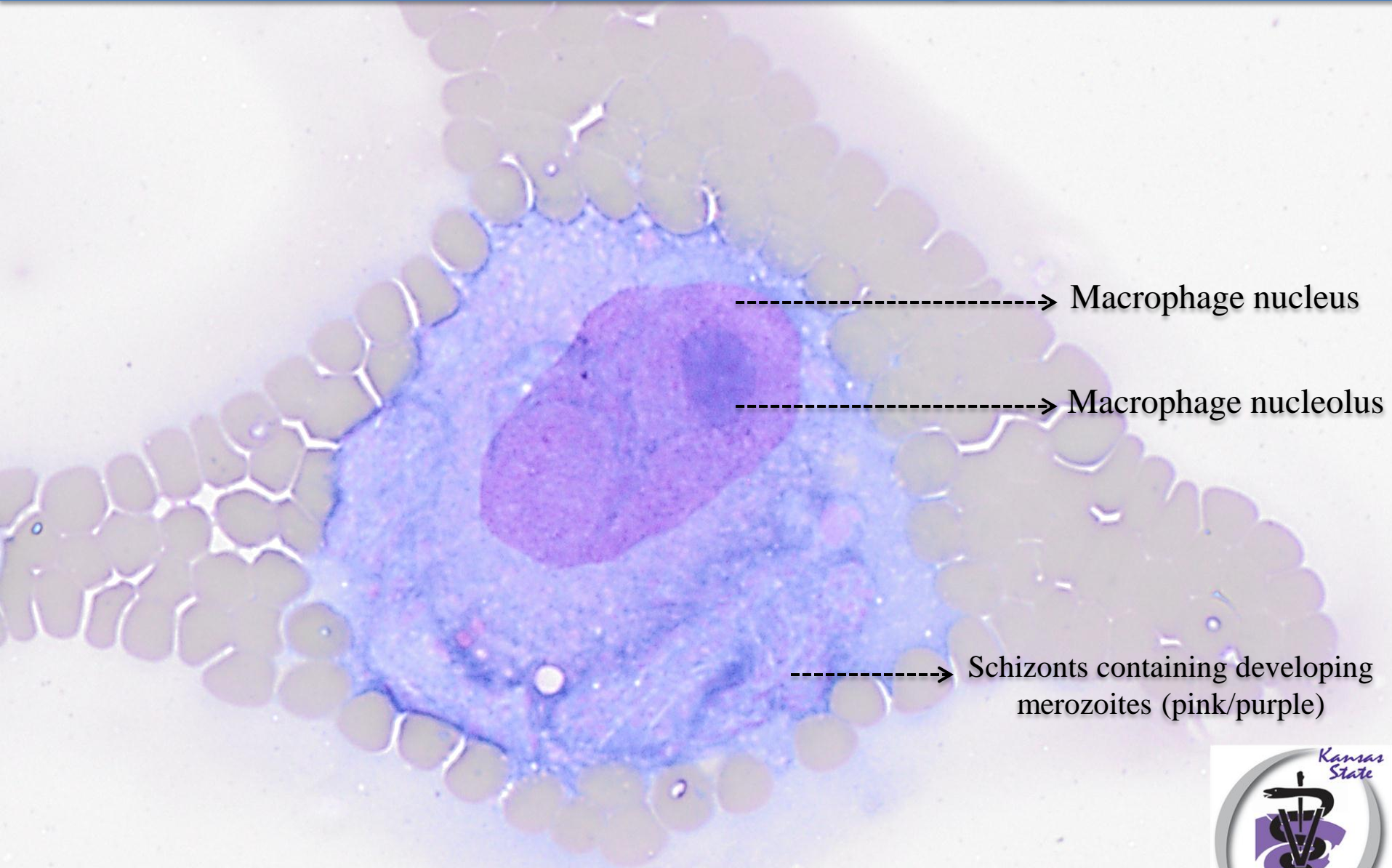
Edge of the blood smear



Clinical Pathology



Schizont – laden macrophage

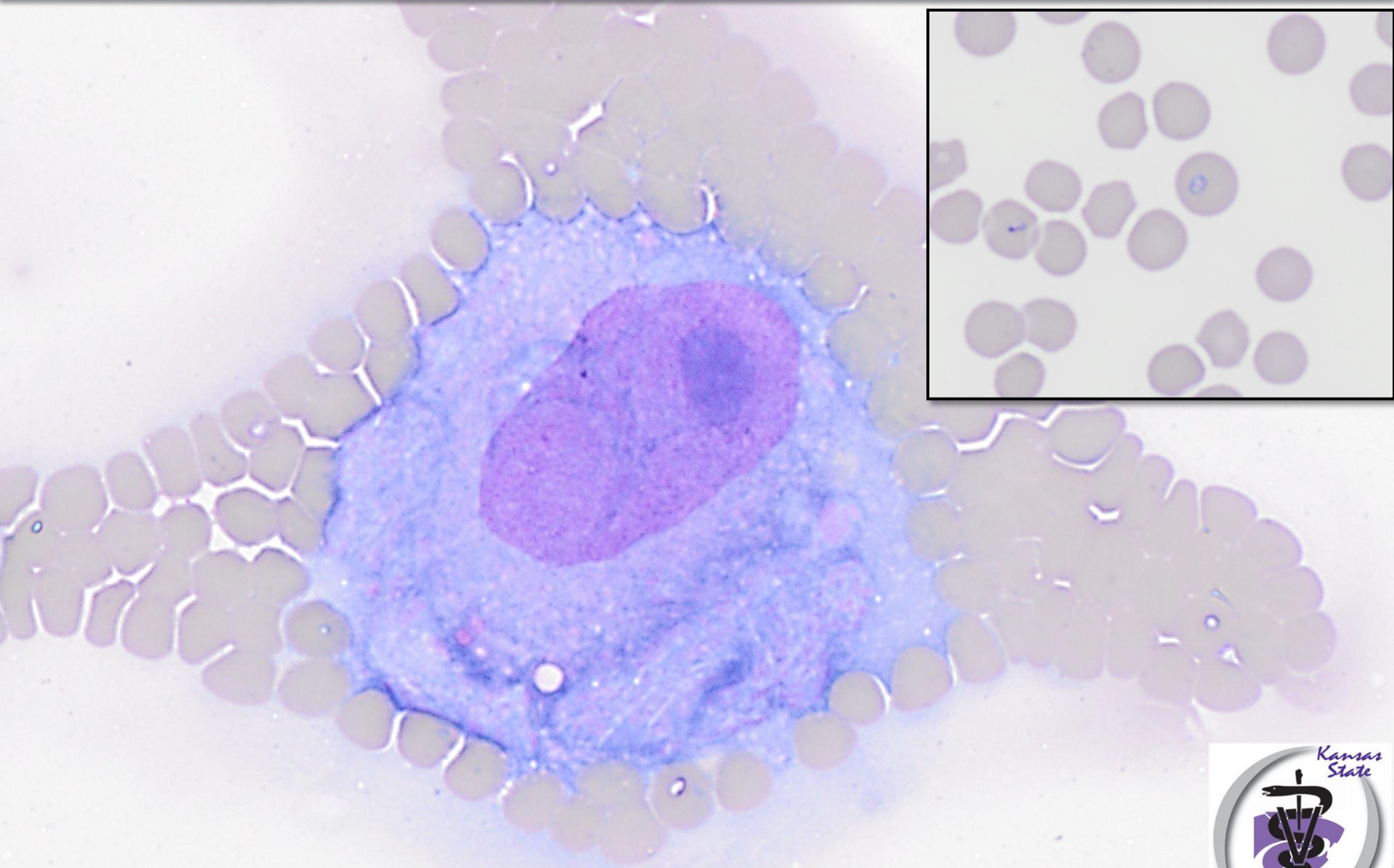


Macrophage nucleus

Macrophage nucleolus

Schizonts containing developing merozoites (pink/purple)

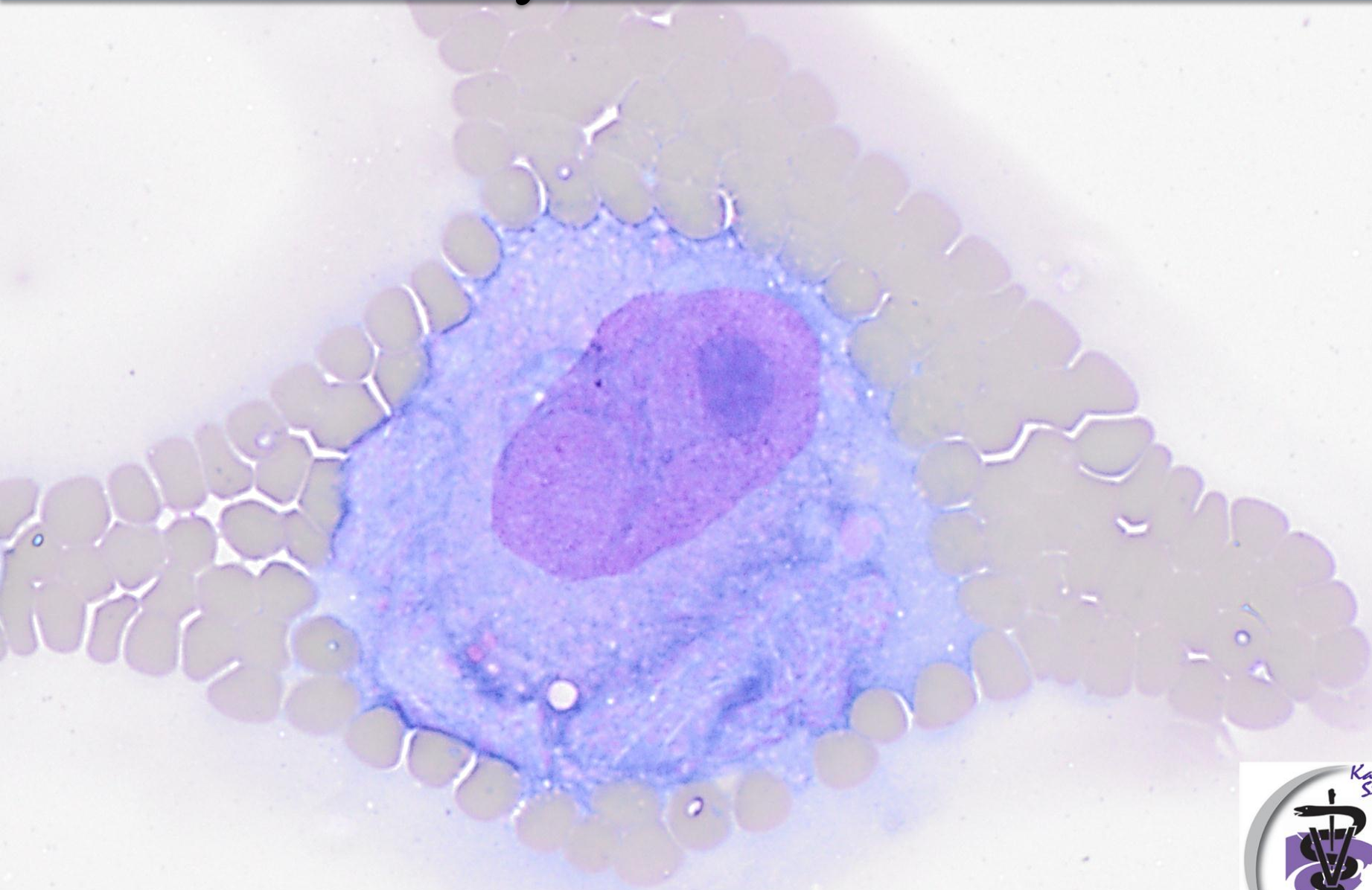
DIAGNOSIS



Clinical Pathology



Cytauxzoonosis



Clinical Pathology

